

Gliomatosis cerebri: A consensus summary report from the First International Gliomatosis cerebri Group Meeting, March 26–27, 2015, Paris, France

Jeffrey P. Greenfield¹ | Alicia Castañeda Heredia² | Emilie George¹ | Mark W. Kieran³ | Andres Morales La Madrid^{2,4}

¹Children's Brain Tumor Project, Department of Neurological Surgery, Weill Cornell Medical College, New York, New York

²Department of Pediatric Hematology and Oncology, Hospital Sant Joan de Deu, Barcelona, Spain

³The Pediatric Brain Tumor Center, Department of Pediatric Oncology, Dana-Farber/Boston Children's Cancer and Blood Disorders Center, Boston, Massachusetts

⁴Division of Pediatric Neuro-Oncology, Department of Pediatric Hematology and Oncology, Hospital Sant Joan de Deu, Barcelona, Spain

Correspondence

Andres Morales La Madrid, Division of Pediatric Neuro-Oncology, Department of Pediatric Hematology and Oncology, Hospital Sant Joan de Deu, Passeig Sant Joan de Deu 2, 08950 Barcelona, Spain.
 Email: amorales@hsjdbcn.org

Abstract

Gliomatosis cerebri (GC) is a universally fatal extensive and diffuse infiltration of brain parenchyma by a glial tumor. Many aspects of this phenomenon remain unknown. The First International Gliomatosis cerebri Group Meeting had the following goals: refine the clinical and radiologic diagnostic criteria for GC, suggest appropriate diagnostic procedures, standardize tissue manipulation for histologic and molecular characterization, and prioritize relevant preclinical projects. Also, general treatment recommendations were outlined for the pediatric population. Importantly, this meeting was the starting point for meaningful collaborative international research projects. This review is a consensus summary of discussions shared and conclusions derived from this meeting.

KEYWORDS

consensus, Gliomatosis cerebri, meeting

ABBREVIATIONS: 18F-FDG PET, deoxyfluoroglucose positron emission tomography; ADEM, acute disseminated encephalomyelitis; ANOCEF, French Neuro-Oncology Registry Database; CNS, central nervous system; CSF, cerebral spine fluid; CT, computed tomography; DIPG, diffuse intrinsic pontine glioma; EGFR, epidermal growth factor receptor; FLAIR, fluid-attenuated inversion recovery; GBM, glioblastoma multiforme; GC, Gliomatosis cerebri; GFAP, glial fibrillary acid protein; HGG, high-grade glioma; IDH1, isocitrate dehydrogenase 1; IHC, immunohistochemical; INA, alpha-internexin; MGMT, O⁶-methylguanine-DNA methyltransferase; MRI, magnetic resonance imaging; MRS, magnetic resonance spectroscopy; MS, multiple sclerosis; OS, overall survival; PDL1, programmed death ligand 1; PTEN, phosphatase and tensin homolog; SIOPE, The European Society for Paediatric Oncology; WHO, World Health Organization

1 | BACKGROUND

No curative options are available for patients who develop growth and invasion patterns compatible with gliomatosis cerebri (GC). Given its low incidence, high mortality, and lack of research projects, little information is available explaining its aggressive biologic behavior. The First International Gliomatosis cerebri Group Meeting held in Paris (March, 2015) was organized and supported by several GC foundations from Europe and North America. It gathered researchers and expert physicians from centers dedicated to pediatric and adult neuro-oncology.

Discussions included clinical, radiologic and morphologic diagnostic criteria (with emphasis to diagnostic procedures and tissue manipulation), pediatric therapeutic recommendations, and relevant collaborative preclinical projects in order to set the background for future translational and clinical research projects.

The term GC was first coined by Nevin in 1938, who described three cases with a diffuse overgrowth of neuroglial cells in wide areas of the cerebral hemispheres.^{1,2} According to the World Health Organization (WHO) 2007 Brain Tumors classification, GC was defined as a diffuse glioma with an extensive infiltration of a large region of the

central nervous system (CNS) with the involvement of at least three contiguous cerebral lobes. Interestingly, the recent 2016 WHO CNS classification has deleted GC as a distinct entity, and rather it has been considered as a widespread and very invasive growth pattern identified rarely in some gliomas.³ It usually has bilateral involvement of the cerebral hemispheres and/or gray matter, with frequent extension to the brain stem, cerebellum, and even—although less frequently—the spinal cord.⁴ Recently, Herrlinger et al.⁵ analyzed the genome-wide DNA methylation and the copy number profiling of 25 adult GC samples. Molecular characterization showed no evidence for a distinct GC-specific molecular subgroup, and all samples could be assigned to well-known molecular subgroups of diffuse gliomas. The authors concluded that GC more likely reflects a diffuse growth pattern that may be detected in different types of histologically and molecularly well-defined glioma entities and does not represent a distinct entity of its own. Similar findings have been published within the pediatric population on the basis of overlapping genetic and epigenetic characteristics with other pediatric gliomas.⁶ This result needs to be reproduced and extended to larger cohorts including adult and pediatric cases. Importantly, GC may not be morphologic entity and may have a similar molecular signature to other high-grade gliomas (HGGs). However, what causes the unique and aggressive infiltrative nature for GC cases remains to be elucidated. Radiologically, GC can be classified in two subtypes: type 1 and type 2 (see Section 3.2).^{7–9} The experts at the conference concurred that GC should be understood not strictly as a radiologic definition but as an entity with a similar infiltrative biologic and clinical aggressive behavior, even though some cases do not fit strictly the classic criteria.

2 | EPIDEMIOLOGY

GC is an extremely rare form of presentation with no specific clinical features. This makes it commonly misdiagnosed, which leads to erroneous or delayed diagnoses. Improving time to diagnosis should be emphasized along with increased awareness among likely providers (neurologists, neurosurgeons, and oncologists). It is unclear if an early diagnosis and timely therapy has an impact on prognosis, but correct identification of GC cases will help prevent inadequate management. It is likely that we do not know GC's true incidence, since several cases have been diagnosed at autopsy.^{7–9} There have been a few relevant series of cases published, composed preponderantly of adult patients. Taillibert et al.¹⁰ reviewed 296 cases in 2006 (206 patients collected from the literature between 1993 and 2004 and 90 cases from the French Neuro-Oncology Registry Database [ANOCEF] Network between 1985 and 2004). They were aged 1 month to 85 years (median 42) with a higher incidence among men than among women (ratio = 1.31). Within the pediatric patient population, George et al.¹¹ recently reviewed the literature spanning a 15-year period (January 2000 to December 2014), a time within which they described 88 pediatric GC patients. Age at the time of diagnosis ranged from 4 months to 21 years with an average age of 11.7 years and a male preponderance. A review of the Weill Cornell Medical College neurological specimen

database was also done, with an additional 10 pediatric cases reported demonstrating the same age range and gender predisposition.

3 | DIAGNOSIS

3.1 | Clinical presentation

GC can imitate a variety of conditions and may present with different symptoms, depending upon the initial neurologic structures involved. Seizures are the most frequent reason for presentation, ranging from a single seizure to status epilepticus. Other presenting symptoms include signs of elevated intracranial pressure or focal neurologic deficits depending upon the involved area. Patients may also present with neurocognitive alteration with poor academic performance and may even mimic dementia; personality and behavioral changes have also been observed.^{7–9,11} Increased awareness of this condition should encourage medical providers to include infiltrative gliomas with GC phenotype in the differential diagnosis of any entity with diffuse brain involvement on imaging with or without the most frequent presenting symptoms.

There are several conditions that can have similar clinical and radiologic diagnostic criteria. It is therefore not unusual for GC patients to have been labeled with other diagnoses and received treatments prior to the correct diagnosis. Among these, viral encephalitis and acute disseminated encephalomyelitis (ADEM) can resemble GC's symptomatology and radiology. GC should also be considered in the differential diagnosis of multiple sclerosis (MS). In children, primary progressive MS should always prompt extensive assessment for alternative diagnoses, including GC. Other pediatric diseases affecting the white matter include leukodystrophies, a heterogeneous group of heritable myelin disorders, which, when being considered, should raise the possibility of GC. Unlike GC, seizures in leukodystrophies are usually a late manifestation. Finally, GC should also be considered in the differential diagnosis of vasculitis.

It is important to emphasize that every time GC is included in the differential diagnosis of a given patient, the patient should be referred to a center with expertise in this condition and surgical biopsy should be considered. Histologic review and molecular characterization have a critical role when suspected. Following these guidelines should be the initial step in the diagnostic evaluation. Equally importantly, tissue analysis will be the only way toward a molecular characterization to allow for advancement beyond our current rudimentary understanding of this condition.

3.2 | Neuroimaging

At clinical presentation, computed tomography (CT) is usually the first imaging obtained due to its availability, rapidity, and low cost. CT findings commonly do not reveal the true extent of the disease and it is not unusual to obtain "normal" reports, particularly in the initial stages. Because of the superiority of detecting white matter abnormalities, magnetic resonance imaging (MRI) is required for diagnosis. MRI findings are characterized by the presence of a diffuse,

infiltrating signal abnormality that involves three or more contiguous cerebral lobes, which is iso- to hypointense on T1, hyperintense on T2, and fluid-attenuated inversion recovery sequences that variably expand the cerebral white matter and have absence or minimal mass effect. It is typically a nonenhancing lesion, but discreet areas of enhancement may be present. While white matter is involved predominantly, gray matter may also be affected. Two types of GC pattern have been distinguished on MRI. Type 1 is the most frequent variant and consists in diffuse neoplastic growth and enlargement of the involved structures without a solid tumor component. Type 2 may represent the local progression of type 1 and is characterized by a more obvious mass in addition to the diffuse component.^{7-9,11-13} GC can be differentiated from multifocal gliomas by its continuity of macroscopic tumor infiltration and through the absence of clear distinction from adjacent normal brain tissue. The role of MRI in prognosis has also been investigated. To date, no imaging findings have been established as predictors for patient survival. Similarly, other techniques such as magnetic resonance spectroscopy (MRS), deoxyfluoroglucose positron emission tomography (18F-FDG PET), and functional diffusion maps have been explored without success.^{7-9,12,13} MRS myoinositol elevation pattern and lack of elevated choline has been suggested as potentially characteristic of GC.¹⁴

3.3 | Histologic, genetic, and epigenetic characterization: The role of tissue sampling

As noted in the earlier sections, the diagnosis of GC is a combination of imaging and pathologic findings. When clinical and radiologic criteria suggest an infiltrative glioma, histologic confirmation through an open or stereotactically guided biopsy is mandatory. However, a number of unique considerations should be taken into account when considering a biopsy. Given the diffuse nature of GC and the fact that gliomas tend to be heterogeneous—even in areas that seem to be similar by imaging—biopsy from a single site can be nonrepresentative of the whole tumor. During the proceeding, there was an extensive discussion about the feasibility and safety profile of performing tissue sampling of more than one area of a suspected lesion, even if only millimeters apart. Consensus from the experts was that if the neurosurgical team feels comfortable with the safety, it would be advisable to obtain *at least* two different biopsy samples using the same needle tract at different tumor depth (using the same burr hole) (Fig. 1) or by sampling two separate tumor sites when using an open approach. This would allow different areas of the lesion to be characterized to address for tumor heterogeneity, histologically and molecularly. There was also agreement that PET/MRI-guided biopsy and novel imaging technologies will be of help in identifying representative areas of the tumor that may increase the yield of this procedure. Molecular markers may be of help when histologic review cannot secure the diagnosis.

Histologically, the main characteristic includes a diffuse pattern of neoplastic glial cells that grow with an absence of well-circumscribed margins. On a macroscopic level, the underlying architecture of brain tissue is attenuated as cells infiltrate it diffusely, but without a definable tumor mass. The infiltration of white matter usually respects nervous fibers, although it can be associated with destruction of myelin

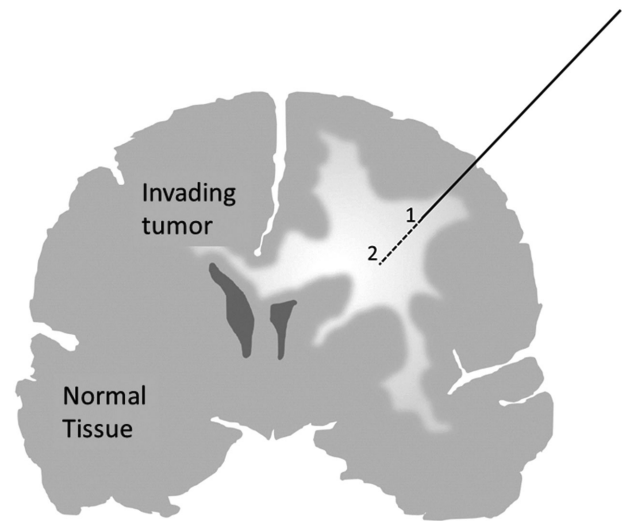


FIGURE 1 Schematic showing a single trajectory path allowing multiple biopsies (in this diagram represented by numbers 1 and 2) to allow for tumor heterogeneity

with preservation of axonal structures. The mitotic index is variable and there is generally no vascular proliferation or necrosis. Expression of glial fibrillary acid protein (GFAP) suggests an astrocytic origin, though in some cases it is scant or absent, with the majority of cases compatible with WHO grade III astrocytoma, but also grade II and IV.¹⁵ Oligodendroglial gliomatosis has also been described. In these cases, biopsies usually demonstrate a uniform population of rounded cells with perinuclear clearing.¹⁶

Very little information is available about the molecular basis of GC. It is likely that similarly to other brain tumors, the molecular profile of adult and pediatric GC will differ. However, very little at all is known about pediatric GC at a molecular level. Ongoing sequencing pediatric GC projects in Europe and North America will surely address this question. Since there is no effective therapy for GCs and there is lack of biologic prognosis factors, it is important to identify immunohistochemical (IHC), molecular, genomic, and epigenomic markers. This will not only be of help in confirming the diagnosis but also allow for a more accurate molecular classification, identification of tumor responses, and hopefully permit design of novel targeted therapy. As of today, there is no consensus regarding the similarities and differences between GC and these other entities (i.e., diffuse intrinsic pontine glioma (DIPG)/glioblastoma multiforme [GBM]), but it is likely that they belong to a spectrum of glial infiltrative neoplasms that share a number of biologic pathways driven by genetic and epigenetic alterations.^{5,6,17-19}

Molecular characterization has given some insight into better prognostication, 1p/19q co-deletion, and isocitrate dehydrogenase 1 (IDH1) somatic mutation; specifically, IDH1^{R132H} mutations have been proposed as favorable prognosis factors in adult studies.²⁰ Within a significant number of GC samples, O⁶-methylguanine-DNA methyltransferase (MGMT) promoter methylation has been found, but its relationship to prognosis has not yet been clearly determined.^{11,17,21,22} There are other nonspecific somatic mutations involved in GC, including epidermal growth factor receptor (EGFR),

phosphatase and tensin homolog (PTEN), and TP53, all of which are well known in other invasive glial tumors. During the meeting, preliminary evidence from the European Society for Paediatric Oncology (SIOPE) GC collaborative review was presented. It included 63 samples from patients with an average age of 13 years (range 3–17 years). Whole-exome sequence data from 10 samples were presented showing, among others findings, a 10% incidence of mutations in H3.3G34 and H3.3K27 and mutations in SETD2 (20%), EGFR (30%), and p53 (40%). These findings signify how crucial it is to obtain adequate tumor tissue, as well as its proper preparation and storage. By storing under ideal conditions in centralized biobanks, next-generation sequencing performed in state-of-the-art research centers is possible. As discussed above, recently published molecular profiling of GC adult cases showed that—not surprisingly—these cases share some of the molecular characteristics identified in other infiltrative gliomas.⁵ Similar results were obtained by molecular profiling a small cohort of pediatric patients, showing that GC in children harbors mutations, oncogene amplifications, and particularly a methylation profile that overlaps with other pediatric HGGs.⁶ However, it is to be established what gives “GC-like” tumors the ability to migrate and aggressively infiltrate throughout normal brain parenchyma. It is likely that GC cases represent one end on the spectra of highly infiltrative HGGs.

4 | IS THERE A “STANDARD OF CARE”?

There is no standard therapy for GC, and all therapeutic interventions are palliative. Given its infiltrative nature, surgery has no role beyond tissue sampling or limited debulking of focal tumor regions causing mass effect. Historically, GC patients have not been included in other HGG trials. Therefore, there is no consensus on the best approach for affected patients. In fact, there was no agreement among experts present in Paris about the real impact that chemotherapy or radiotherapy may have on this disease.^{23–27}

After confirming the diagnosis of GC based on imaging and histologic review, the panel of experts recommended the administration of upfront “institutional” chemotherapy used for HGG. Even though a few trials have attempted to establish the best chemotherapy approach for GC, there is insufficient data to recommend a specific combination. The NOA-05 Phase 2 Trial of procarbazine and lomustine therapy in adult GC²³ was the first multicenter prospective trial in this patient population. Its primary endpoint was to determinate the percentage of patients without therapy failure within 8 months (four cycles of procarbazine/lomustine) from enrollment. Thirty-five patients were included with a median age of 50 years. Failure-free survival at 8 months was observed in 50.3% patients and the median progression-free survival was 14 months. The median overall survival (OS) was 30 months, which compared favorably to those reported in retrospective studies that have a median OS of 11–24 months.²³ Other studies reporting chemotherapy effectiveness in GC have been published with similar poor responses.^{24,25}

With respect to radiation therapy, the panel of experts felt that although it appears to be effective in delaying disease progression, the optimal timing remains unclear. Many patients with minimal symptoms

at diagnosis may have significant worsening of quality of life with radiation as a result of the high doses and very large fields required. Radiation therapy may therefore be more appropriate at the time of progression. In children, the concern for long-term neurocognitive impairment associated with radiation therapy is important, but it may be less of an issue in this disease because survival from invasive gliomas is rare. Anti-angiogenic therapies such as bevacizumab have not proven to be effective in this disease (Wen P, et al., unpublished data). Low vascularization and absence of contrast enhancement may explain the perception of a lack of benefit from this strategy. Furthermore, there are concerns that bevacizumab therapy may be associated with the development of an even more invasive phenotype.²⁸

Tumor evolution is a well-documented phenomenon and particularly relevant at tumor progression. If we are going to design future clinical trials utilizing novel targeted therapies, it is paramount that our targets are present in the tumor *at the moment* we are administering a specific targeted therapy. It is likely that several targeted therapy trials have failed because testing performed in diagnostic tissue identified a molecular target that may have become less relevant at the time of progression. Clearly, multiple biopsies at diagnosis and progression can add to patient risk and should be done in centers with appropriate expertise. Doing so would allow for the evaluation of tumor evolution induced by chemotherapy or radiotherapy and redefinition of “druggable” molecular targets in real time. Important ethical and safety considerations will have to be addressed when considering these sequential procedures, ideally within the context of a clinical trial.

As demonstrated through the efforts from DIPG research where both upfront pretherapy biopsy and postmortem collection of tissue have been obtained, comprehensive longitudinal studies can be performed at the molecular level.²⁹ It is likely that with tissue at diagnosis, at progression and at postmortem, we will be able to begin the process of understanding how to identify critical pathways offering an advantage for tumor growth or resistance to treatment. This accumulating knowledge will provide an insight into invasive gliomas biology and will be of help in identifying new and more effective therapies.

4.1 | Novel therapeutics

Immunotherapy has generated significant interest recently due to remarkable responses in a few diseases (in particular lymphomas and melanoma) and was widely discussed at the conference. It is becoming implemented in cancer trials worldwide and may have utility in extensive infiltrative gliomas where the possibility of identifying and attacking the diffuse invasion associated with these tumors could be important. In GBM, it has been described that the loss of PTEN may result in overexpression of programmed death ligand 1 (PDL1); this can be used to depress cytotoxicity of lymphocytes in the tumor microenvironment and, in combination with radiotherapy, may have therapeutic synergism. IDH1 mutations are now considered the hallmark of adult type diffusely infiltrating astrocytomas and have also been identified in a percentage of GC cases.^{5,6,30} IDH-targeting therapies are currently under study and several trials using these inhibitors and immunotherapy targeting the mutant IDH1 protein are being developed.^{31,32} Epigenetic alterations have also been shown to be highly relevant,

particularly in HGGs.^{17,18,21,22} Therefore, exploring epigenetic modifiers could be of significant relevance.

A lack of established GC cell lines or animal models is a significant roadblock toward progress. A major effort must be made to develop preclinical models for studying migration patterns with functional experiments.

5 | PROGNOSIS

GC has a dismal prognosis, with a median OS in adult series of 9.5–23.7 months. A recent analysis of pediatric patients showed a median progression-free survival of 11 months with a range from 0 to 18 months and a median OS of 17 months with a range from 3 to 52 months.¹¹ This study identified young age, good performance status, and low-grade histology as favorable prognostic factors. Desesret et al.²⁰ describe alpha-internexin (INA) expression and IDH1^{R132H} mutation as favorable prognosis factors. As of today, little else is known about other prognostic surrogates. Importantly, a multidisciplinary approach with the involvement of a palliative care unit and psychological support for the patients and families is a priority.

6 | WORKING TOWARD A GC REGISTRY, MOLECULAR CHARACTERIZATION, AND FUTURE TRENDS

Establishing a centralized biobank and database for patients with GC worldwide is necessary to uncover the molecular information desperately needed on GC through an open-source format. The first international registry for GC was launched in 2015 (gcregistry.com), with over 50 registrants enrolled in the first year. Our goal is to establish patient and tissue referral centers, two in Europe (London and Heidelberg) and one in the United States (New York), that would centralize clinical, radiologic, and, most importantly, tumor tissue banking to coordinate molecular characterization. This will potentially identify targets for novel therapies. Only then, we will be in a position to launch a multi-institutional international clinical trial. This approach will allow consultation with physicians and researchers worldwide about individual cases of GC and provide a hub for patients and families confronting the diagnosis to find support from others and eventually to learn about new clinical trials.

Invasive infiltrative pediatric HGG continues to be an orphan disease with grim prognosis. With extensive molecular profiling of more cases, it will be feasible to determine whether GC should be maintained a separate clinical entity or if it represents the most infiltrative form of HGGs. Centralization and open-source data will allow experts worldwide to analyze these cases appropriately using current standard methods as well as through single-cell sequencing, DNA, RNA, and protein sequencing of the tumor, and through investigation of tumor markers from tumors, cerebral spine fluid, and blood. Obtaining samples not only at the time of diagnosis but also, if possible, at progression and at

autopsy will be crucial toward establishing a better understanding of invasive gliomas biology.

List of participants of the First International Gliomatosis cerebri Group Meeting, March 26–27, 2015, Paris, France:

Eric Bouffet, Hospital for Sick Children, Canada
 Franck Bourdeaut, Institut Curie, France
 Alberto Broniscer, St. Jude Children's Research Hospital, USA
 Alicia Castañeda, Hospital Sant Joan de Déu, Spain
 Kenneth Cohen, John Hopkins Children's Center, USA
 Ofelia Cruz, Hospital Sant Joan de Déu, Spain
 Ira Dunkel, Memorial Sloan Kettering Cancer Center, USA
 Nicholas Foreman, Children's Hospital Colorado, USA
 Maryam Fouladi, Cincinnati Children's Hospital Medical Center, USA
 Maria Luisa Garrè, Gaslini Institute, Italy
 Umberto De Girolami, Dana-Farber Cancer Institute, USA
 Stewart Goldman, Lurie Children's Hospital of Chicago, USA
 Jeffrey Greenfield, Weil Cornell Medical Center, USA
 Jacques Grill, Institut Gustave Roussy, France
 Darren Hargrave, Great Ormond Street Hospital, UK
 Cynthia Hawkins, Hospital for Sick Children, Canada
 Chris Jones, The Institute of Cancer Research, UK
 David Jones, Research Center (DKFZ) Heidelberg, Germany
 Yasmin Khakoo, Memorial Sloan Kettering Cancer Center, USA
 Mark Kieran, Dana-Farber/Boston Children's Hospital, USA
 Christof Kramm, Georg-August-Universität Göttingen, Germany
 Michelle Monje, Lucile Packard Children's Hospital Stanford, USA
 Ángel Montero, Hospital Sant Joan de Déu, Spain
 Andrés Morales, Hospital Sant Joan de Déu, Spain
 Roger Packer, Children's National Medical Center, USA
 Luis Parada, UT Southwestern, USA
 Torsten Pietsch, Universität Konstanz, Germany
 Stephanie Puget, Hopital Necker—Enfants Malades, France
 Nathan Robison, Children's Hospital Los Angeles, USA
 Dannis G. van Vuurden, VU University, The Netherlands
 Monika Warmuth-Metz, Universitäts-klinikum Würzburg, Germany
 Kathy Warren, NIH/ NCI, USA
 Patrick Y. Wen, Dana-Farber Cancer Institute, USA

ACKNOWLEDGMENTS

Grateful support provided by the following GC advocacy and research collaboratives: Elizabeth's Hope (USA); Children's Brain Tumor Project (USA); AYJ Fund (USA); Izas la Princesa Guisante (Spain); Franck un rayon de soleil (France).

CONFLICT OF INTEREST

The authors that there is no conflict of interest.

REFERENCES

1. Nevin S. Gliomatosis cerebri. *Brain*. 1938;61:170–191.
2. Nevin S. Thalamic hypertrophy or gliomatosis of the optic thalamus. *J Neurol Psychiatry*. 1938;1(4):342–358.

3. Louis DN, Perry A, Reifenberg G, et al. The 2016 World Health Organization Classification of Tumors of the Central Nervous System: a summary. *Acta Neuropathol.* 2016;131:803–820.
4. Louis DN, Ohgaki H, Wiestler OD, et al. The 2007 WHO Classification of Tumours of the Central Nervous System. *Acta Neuropathol.* 2007;114:97–109.
5. Herrlinger U, Jones DTW, Glas M, et al. Gliomatosis cerebri: No evidence for a separate brain tumor entity. *Acta Neuropathol.* 2016;131(2):309–319. PMID 26493382
6. Broniscer A, Chamdine O, Hwang S, et al. Gliomatosis cerebri in children shares molecular characteristics with other pediatric gliomas. *Acta Neuropathol.* 2016;131(2):299–307.
7. Chamberlain MC. Gliomatosis cerebri: Better definition, better treatment. *Neurology.* 2004;63:204–205.
8. Rudà R, Bertero L, Sanson M. Gliomatosis cerebri: A review. *Curr Treat Options Neurol.* 2014;16:273–282.
9. Chen S, Tanaka S, Giannini C, et al. Gliomatosis cerebri: Clinical characteristics, management and outcomes. *J Neurooncol.* 2013;112(2):267–275.
10. Taillibert S, Chodkiewicz C, Laigle-Donadey F, Napolitano M, Cartalat-Carel S, Sanson M. Gliomatosis cerebri: A review of 296 cases from the ANOCEF database and the literature. *J Neurooncol.* 2006;76:201–205.
11. George E, Settler A, Connors S, Greenfield JP. Pediatric Gliomatosis cerebri: A review of 15 years. *J Child Neurol.* 2015.
12. Del Carpio-O'Donovan R, Korah I, Salazar A, Melançon D. Gliomatosis cerebri. *Radiology.* 1996;198:831–835.
13. Yu A, Li K, Li H. Value of diagnosis and differential diagnosis of MRI and MR spectroscopy in Gliomatosis cerebri. *European Journal of Radiology.* 2006;59:216–221.
14. Mohana-Borges AV, Imbesi SG, Dietrich R, Alksne J, Amjadi DK. Role of proton magnetic resonance spectroscopy in the diagnosis of gliomatosis cerebri: a unique pattern of normal choline but elevated Myoinositol metabolite levels. *Comput Assist Tomogr.* 2004;28:103–5.
15. Sanson M, Napolitano M, Cartalat-Carel S, Taillibert S. La gliomatose cérébrale. *Rev Neurol (Paris).* 2005;161(2):173–181.
16. Pal L, Behari S, Kumar S, Kumar R, Shankar SK, Gupta RK. Gliomatosis cerebri: An uncommon neuroepithelial tumor in children with oligodendroglial phenotype. *Pediatr Neurosurg.* 2008;44:212–215.
17. Brennan CW, Verhaak RG, McKenna A, et al. The somatic genomic landscape of glioblastoma. *Cell.* 2013;155(2):462–477.
18. Cuddapah VA, Robel S, Watkins S, Sontheimer H. A neurocentric perspective on glioma invasion. *Nat Rev Neurosci.* 2014;15:455–465.
19. Salhia B, Rutten F, Nakada M, et al. Inhibition of rho-kinase affects astrocytoma morphology, motility, and invasion through activation of Rac1. *Cancer Res.* 2005;65(19):8792–8800.
20. Desestret V, Ciccarino P, Ducray F, et al. Prognostic stratification of gliomatosis cerebri by IDH1R132H and INA expression. *J Neurooncol.* 2011;105:219–224.
21. Zhang K, Wang XQ, Zhou B, Zhang L. The prognostic value of MGMT promoter methylation in glioblastoma multiforme: A meta-analysis. *Fam cancer.* 2013;12:449–458.
22. Sturm D, Bender S, Jones DT, et al. Paediatric and adult glioblastoma: Multiform (epi)genomic culprits emerge. *Nat Rev Cancer.* 2014;14(2):92–107.
23. Glas M, Bähr O, Felsberg J, et al. NOA-05 phase 2 trial of procarbazine and lomustine therapy in gliomatosis cerebri. *Ann Neurol.* 2011;70:445–453.
24. Sanson M, Cartalat-Carel S, Taillibert S, et al. Initial chemotherapy in gliomatosis cerebri. *Neurology.* 2004;63:270–275.
25. Levin N, Gomori JM, Siegal T. Chemotherapy as initial treatment in gliomatosis cerebri: Results with temozolamide. *Neurology.* 2004;63:354–356.
26. Kong DS, Kim ST, Lee JI, et al. Impact of adjuvant chemotherapy for gliomatosis cerebri. 2010;10:424–429.
27. Mattox AK, Lark AL, Adamson DC. Marked response of gliomatosis cerebri to temozolamide and whole brain radiotherapy. *Clin Neurol Neurosurg.* 2012;144:299–306.
28. Salloum R, DeWire M, Lane A, et al. Patterns of progression in pediatric patients with high grade glioma or diffuse intrinsic pontine glioma treated with Bevacizumab-based therapy at diagnosis. *J Neurooncol.* 2015;121:591–598.
29. Kambhupati M, Perez JP, Yadavilli S, et al. A standardized autopsy procurement allows for the comprehensive study of DIPG biology. *Oncotarget.* 2015;6:12740–12747.
30. Ichimura K, Narita Y, Hawkins CE. Diffusely infiltrating astrocytomas: Pathology, molecular mechanisms and markers. *Acta Neuropathol.* 2015;129:789–808.
31. Rohle D, Popovici-Muller J, Palaskas N, et al. An inhibitor of mutant IDH1 delays growth and promotes differentiation of glioma cells. *Science.* 2013;340:626–630.
32. Schumacher T, Bunse L, Pusch S, et al. A vaccine targeting mutant IDH1 induces antitumor immunity. *Nature.* 2014;512:324–327.